

*Robt. A. Conley*

BULLETIN No. 72.

JULY, 1896.

ALABAMA

# Agricultural Experiment Station

OF THE

AGRICULTURAL AND MECHANICAL COLLEGE,

AUBURN.

---

---

A Study of Skin Tumors of Horses and Mules  
in Alabama.

---

---

S. L. COLEMAN.

MONTGOMERY, ALA.:  
THE BROWN PRINTING COMPANY, PRINTERS.  
1896.

---

---

**COMMITTEE OF TRUSTEES ON EXPERIMENT STATION.**

I. F. CULVER.....Union Springs.  
J. G. GILCHRIST.....Hope Hull.  
H. CLAY ARMSTRONG.....Auburn.

---

**STATION COUNCIL.**


WM. LEROY BROWN.....President.  
P. H. MELL.....Botanist.  
B. B. ROSS.....Chemist.  
L. M. UNDERWOOD.....Biologist.  
C. A. CARY, D. V. M.....Veterinarian.  
J. F. DUGGAR.....Agriculturist.  
F. S. EARLE.....Horticulturist.

**ASSISTANTS.**

J. T. ANDERSON.....First Assistant Chemist.  
C. L. HARE.....Second Assistant Chemist.  
R. G. WILLIAMS.....Third Assistant Chemist.  
T. U. CULVER.....Superintendent of Farm.

---

---

 The Bulletins of this Station will be sent free to any citizen of the State on application to the Agricultural Experiment Station, Auburn, Alabama.

---

---

# A STUDY OF THE SKIN TUMORS OF HORSES AND MULES IN ALABAMA.\*

—BY—

S. L. COLEMAN.

It is my endeavor to give the results of my investigations of the common skin tumors which are so frequently found upon horses and mules that are brought to the free clinics for treatment.

I have made no new discoveries as to the origin and cause of these tumors, nor do I desire to advance any new theories as to their origin; but, by the advice of Dr. Cary who has kindly furnished me with the material for the study, I have attempted (by collecting several of these tumors from different animals, and studying them individually and collectively with special reference to their history and their macroscopical and microscopical appearances) to place them under their proper classification. In the first place, as their name indicates, they are tumors; that is, they are neoplasms or pathological growths of an embryonal character, developing without inflammation. This variety of tumor is almost painless; it is, of course, not entirely devoid of sensation; it may be more sensitive than normal skin; yet, when compared with most sacomas and carcinomas, it may be called painless. These neoplastic growths are tumor-like in their origin; that is, they originate without any apparent cause—somewhat spontaneously. We do not know why or how they orig-

\* Mr. S. L. Coleman was a post-graduate (1895-96) in the A. and M. College at Auburn, Ala., and worked up this bulletin as a thesis for a post-graduate degree while studying histology, pathology and bacteriology in the Veterinary Department.—C. A. C.

inate ; but their history proves them to be non-hereditary. So far as we can learn by the aid of the microscope, they are not caused by parasites, and they are not of a nervous origin. However, there is some slight indication that they may be of a mechanical or inflammatory origin ; but admitting this, it would not give us all the causal factors ; since there must have been some unknown favorable condition of the system to produce the morbid growth that follows the mechanical irritation. These tumors are very frequently found upon regions of the body which, on account of their location, are little liable to irritation. For instance, in several cases which were brought to the college free clinic, these tumors were found upon the ears, the breast, the inside of the legs and on the sides of the neck—places little liable to irritation ; hence, could not be so produced except by uncommon accidental mechanical irritation. It is true that after the tumors have begun to grow, mechanical irritation will augment their development, cause them to grow more rapidly and larger.

These tumors are composed of multiplying or proliferating cells ; the growth or enlargement is not due simply to an increase in the size of the individual tumor cells, but to a multiplication and enlargement of the cells.

These tumors are vascular ; are supplied with nutrient blood by branches from the vessels of the subcutaneous connective tissue, in which they are generally found imbedded.

The shape of these tumors depends upon their location ; as a rule, they approximate a spherical form. If they are crowded or pressed by a limb or by another tumor, they will assume a shape corresponding to the pressure to which they are subjected ; hence, they may be oval, pear shaped, or somewhat flattened, but when they occur on a free surface they generally approximate a spherical form.

According to one classification, tumors are divided into three groups :

1. The Simple or Histoid tumors which are composed

almost entirely of the tissues of which the body is composed, generally of some form of connective tissue; such as neuroglia, bone, cartilage, white fibrous tissue, or adipose tissue.

2. The Sarcomatous tumors are composed largely of embryonic tissues, which may, in some cases, reach a partial development, but the growth of the tissues always stops before reaching the highest stage of development.

3. Carcinomas or Cancerous tumors are those in which any of the elementary tissues of the body may be present, but these tissues are present usually in an erratic manner.

Since the morbid skin growths have been classified as tumors, the question arises, to which of the above three groups do the skin tumors belong?

Some writers classify similar tumors under the head of fibromas (fibrous tumors); others take a stand half way between the first and second groups and call them sarco-fibromas. Evidently, it is rather difficult to distinguish between a young or embryonal fibroma and a spindle-celled sarcoma. A spindle-celled sarcoma is composed of young or embryonal fibrous connective tissue cells; the embryonal or young fibroma contains young fibrous connective tissue cells very like those found in a spindle-celled sarcoma. However, after the fibroma has reached a greater degree of maturity, it is comparatively easy to distinguish it from a sarcoma.

In none of the cases, which I have studied with the microscope, have I found anything characteristic of the sarcoma; but in every case, as I hope to show by the accompanying plates, I have found them to be distinctly fibromatous, fibrous tumors.

The fibromas are divided into the hard and soft variety.

The soft fibroma is nothing more or less than young connective tissue; the tumor contains more cells than fibres, and its cellular elements are not so highly developed as in the hard fibroma. The soft fibroma bears a greater similarity to the sarcoma than the hard fibroma.

A careful study of the microscopical sections (illustrated by the accompanying plates) proves, beyond question, that these tumors are distinctly fibromas; some of them approach more nearly the soft variety, while others are evidently hard fibromas.

The seat of the fibroma is in the mucous, the muscular or the subcutaneous connective tissue. All of the tumors or fibromas, studied by me were found in the subcutaneous connective tissue. But the sarcoma is also found in this same locality, so that we find nothing peculiar about the seat of these skin tumors to preclude the possibility of their being sarcomas.

*Macroscopical Characteristics.*—As before mentioned, these skin tumors vary in size and shape. Some of the young tumors are less than one-fourth of an inch in diameter, while others may be three or more inches in diameter. They are all somewhat spherical in form, but their shape is determined largely by the pressure of the surrounding tissues.

As a rule, more than one of these tumors appear on an animal at one time. In all cases that I have observed and investigated there were several tumors found on the same animal. In one instance, there were more than fifty tumors cut from one mule. However, it is not always the case that these tumors are multiple; but, in rare instances, a single tumor may be found on an animal.

These tumors varied somewhat in their action under the knife. In some cases the spherical, shining pearl-like tumors popped out with slight pressure as soon as the knife cut through the thin capsules or the skin overlying them. Other tumors belonging to the same group would require the knife to sever them from their connection with the surrounding tissue.

When microscopic sections were cut of these tumors, I found that each section presented a white shining waxy appearance. On pressure, these tumors vary in their relative degree of consistency; but, as a rule, they are quite firm.

*Microscopical Characteristics.*—An examination of thin sections of these tumors, with the microscope, show that they consist principally of dense bundles of white fibrous tissue, which in some cases presents a somewhat embryonal appearance; but still the tissue is too highly developed to admit the tumor to the group of sarcomas.

In the case of fig. 9 we have a section through a collection of young skin tumors, which have just burst through the skin. Note in fig. 9, A, the fibrous capsules encircling the little embryonal tumors. Fig. 9, C, shows the character of the tissue of the young tumors, when magnified 534 diameters; while D shows the character of the encircling capsules when magnified the same number of diameters. Also, note that in all these cuts the fibrous bundles, of which the tumors are largely composed, run in various directions. Furthermore, notice that these tumors, as a rule, are not very vascular; and that the blood vessels, which they do contain, have not very highly organized or developed walls.

Nos. 2, 3, 4, 5, show very few blood vessels.

Fig. 9, B, represents two arteries, a cross section of one and a longitudinal or oblique section of the other. The two vessels are in the subcutaneous connective tissue and not in the tumor proper. This illustration is given to show the difference between the degree of development of the walls of the blood vessels in the surrounding normal tissues and the tumor proper.

In almost every point these tumors agree microscopically with the fibroma. Their highly developed white fibrous connective tissue cells, and the general lack of embryonal sarcomatous cellular character will serve to distinguish them from the sarcoma. Moreover, the sarcoma is always very vascular, much more so than the average fibroma.

I learned from the clinical experience of Dr. Cary, that these tumors have never given metastasis; that is, they have never extended to internal organs or surfaces. This is another point which goes to prove that they are not sarcomas. The only sarcoma that recurs without metastasis

is the myeloid or giant celled variety. But the common skin tumors do not in the least resemble this variety of sarcoma. So far as I can see, there is only one point of resemblance between these skin tumors and the spindle-celled sarcoma. The embryonal cells in the young skin tumor may resemble the spindle cells of a sarcoma; but the tissues surrounding these cells and the further development of the cells in the fibroma prove conclusively that the young skin tumors are not sarcomas.

After the removal of one of these skin tumors, a peculiar tumor may form in its place, which is nothing more or less than an abnormal growth of granulation tissue, or "proud flesh" as it is commonly called. These exuberant granulation tumors occur in the following way: When the original skin tumor is removed, the cavity must be filled up and closed by granulation tissue, forming what is commonly known as scar tissue. Layer after layer of embryonal granulation cells are formed on the sides and bottom of the wound, made by the excision of the original tumor. (Sometimes the original tumor drops out or is torn out leaving a wound very similar to, but smaller than, the wound usually made when the tumor is cut out.) The layers of granulation cells are supplied with nutriment by the loops of capillary blood vessels; new capillary loops accompany the rapidly growing, dividing embryonal granulation cells. But, before the lips of the wound unite, there must be a formation of epithelium, either from the extension of the epithelial cells on the edges of the wound or from the granulation cells. When the epithelium is formed by neither of these processes, we have, as a result, a growth of what is called exuberant granulations or "proud flesh." If the wound is irritated by the animal's biting or rubbing it, and possibly by the action of septic germs, this epithelial covering can not be formed. In other words, periodic irritation will prevent the healing of a wound and produce a granulation tumor.

Some sarcomas are composed largely of embryonal con-



nective tissue cells; granulation tumors are composed of very similar embryonal cells; hence, the latter are sometimes called sarcomas. It may be that an examination of these secondary granulation tumors has led some observers to classify the common skin tumors under the head of sarcomas.

The common skin tumors are frequently called warts, and this mistake is due to the fact that many persons designate all surface tumors as warts.

The wart is technically called a papilloma; its prototype is the papillae of the skin. The connective tissue sends up papillae which become greatly enlarged and are supplied with a network of blood vessels from the subcutaneous connective tissue. These enlarged papillae become surrounded with epithelium which varies in character with the location; for instance, if the papilloma is on the skin it is surrounded with flat scale-like epithelium, but if it is on a mucous membrane it is surrounded with a thinner and more delicate capsule. The papilloma (wart) of the skin is usually much smaller and less vascular than the skin tumors of fibromas. In some instances it may require a microscopical examination to determine whether a tumor is one of these fibromas or a papilloma.

#### TREATMENT.

1. *Surgical*.—First, cut away the long matted and filthy hair around the tumor; clean the tumor and the surrounding skin with soap and water and then apply some antiseptic; such as, a two per cent. creolin solution, or 1 to 1000 mercuric chloride solution. Take the knife in the right hand, cut the skin from around the tumor, preserving as much of the skin as possible, but taking great care to remove completely all of the morbid growth. In most cases where the skin has not been broken, the tumor will pop out as soon as an incision is made through the skin and the capsule, and a little pressure is applied. In other cases, the knife must be used to remove the tumor from its at-

tachment to the surrounding normal connective tissue. Where the tumor is quite small it may be cut out with the curved scissors; this, of course, will remove a small amount of skin that surrounds and covers the tumor. In some instances, where the tumor has broken through the skin and has grown to any size, it may be torn from its attachment by a sudden pull with the hand. Occasionally, the tumor may have dropped out or have been cut out and its place filled with exuberant granulations; in such cases the superfluous granulations may be removed with the knife, the scissors, or the curette. After completely removing the tumor, apply strong carbolic acid, or pulverized copper sulphate. These may be applied and held in place for a short time by means of a small pledget of cotton.

The after treatment consists in cleaning the wound once per day with clean cotton, and water that has been boiled and cooled; then apply enough to cover the surface, of one of the following prescriptions:

- (a) R. Creolin..... 4 fluid drachms.  
 Glycerine. .... 3 fluid ounces.  
 Pure water..... 1 pint.

Mix. Apply after cleansing the wound as above directed.

- (b) R. Carbolic acid..... 2 fluid drachms.  
 Zinc sulphate..... 4 drachms.  
 Glycerine ..... 3 fluid drachms.  
 Pure water ..... 1 pint.

Mix. Apply as directed for (a).

- (c) R. Iodoform..... 1 drachm.  
 Tannic acid..... 3 drachms.  
 Sulphur..... 1 ounce.  
 Vaseline ..... 1 “

Glycerine, quantity sufficient to make make  
 a free flowing mixture (6 to 12 fluid ounces).

Mix. Apply as directed for (a).

2. *Potential Cautery or Sloughing.*—This method of treatment may be used when the knife is considered dangerous,

because the operator is inexperienced or the base of the tumor is very large and too much bleeding would follow the use of the knife.

Clean the tumor and the skin around it with soap and water; oil the skin around the tumor with lard or vaseline; cover the raw tumor with a thick layer of pulverized copper sulphate; place a large wad of cotton over the tumor and hold it in place by a bandage applied very tightly. (Avoid cutting off the circulation by having a broad bandage and plenty of cotton under the bandage during its application.) Leave this bandage on for a week; keep the animal standing as quietly as possible, tied in a single stall. At the end of a week, remove the bandage and if the tumor can not be readily pulled away with the fingers, apply the pulverized copper sulphate, the cotton and the bandage as before. Keep up these weekly applications until the tumor is entirely gone; then treat the wound with prescription (a), (b) or (c). It may be well to state that the bandage must be kept fixed or it will irritate and thus stimulate the growth of the tumor.

This method of potential cautery can be used only when the tumor is on a limb or in some place where a bandage can be readily applied. In places where a bandage can not be applied, the following caustic may be used:

R. Arsenious acid (white arsenic)...	4 drachms.
Caustic potash (stick).....	2 “
Gum arabic.....	4 “
Pure water.....	1 fluid ounce.

Mix and label “Poison.” Thoroughly clean the tumor and the skin around it; oil the skin around the tumor with lard or vaseline; apply with a swab a thick layer of the sticky mixture all over the free and raw surface of the tumor; tie the animal’s head so that it can not reach the tumor with its mouth, at least for one day. (In fact, it is essential to devise some means to prevent the animal from biting or gnawing the tumor or the healing wound, all the time.) In ten or twelve days, the whole tumor or part of it

that has been destroyed by the arsenic, may be pulled or torn away by the fingers. In case the tumor is not all destroyed by the first application, apply it again, being very careful to cover the skin around the tumor with lard or vaseline previous to the application in all instances. Never apply this very strong caustic a second time sooner than twelve to twenty days after the first application. Usually, one application is sufficient. On the abdomen, the lips, the cheeks and the eye-lids, this remedy should be used with great caution, because it is liable to make a hole entirely through the walls of these parts.

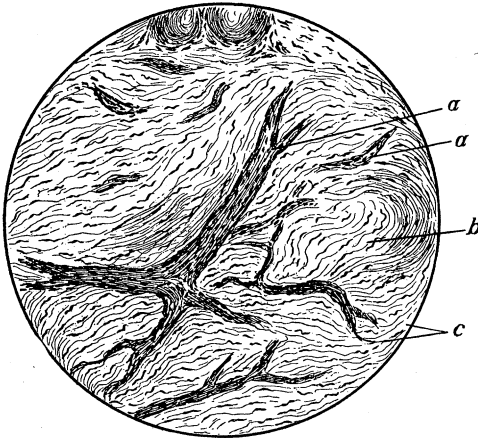
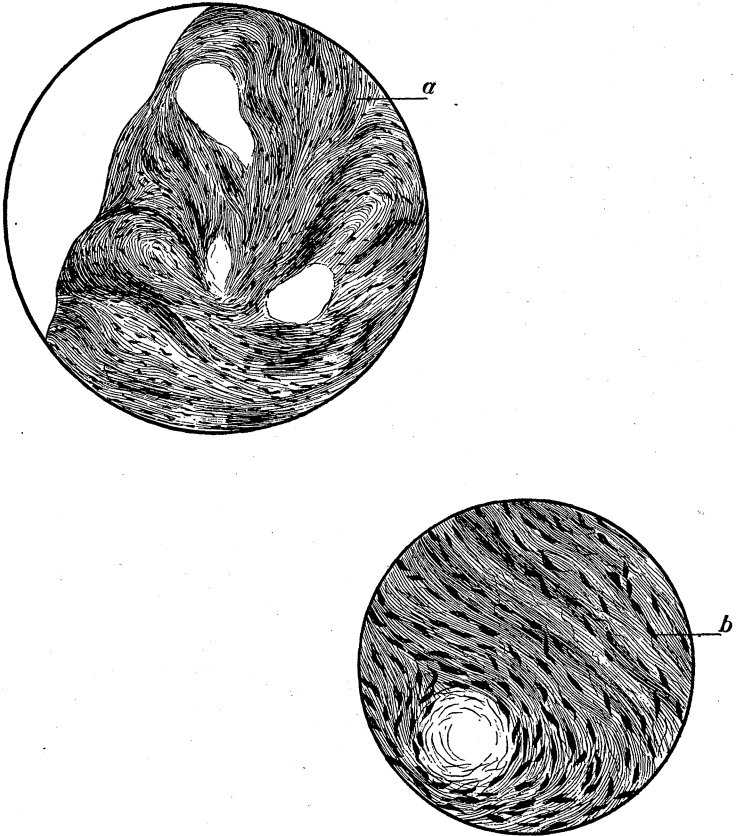
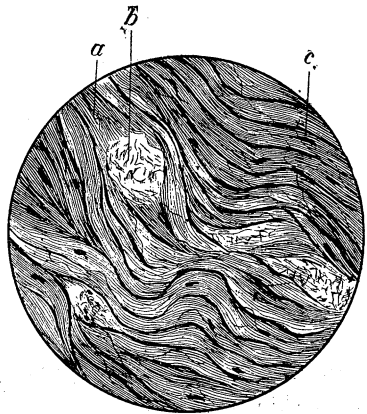



FIG. 1.—Section of tumor from side of mule. Tumor, 3 inches in diameter. *a, a*, blood vessels situated between the fibrous bundles; walls of vessels not well developed; *b*, fibrous tissue; the fibres running in various directions. Magnified 74 diameters and nuclei brought out with borax carmine.



FIG'S. 2 AND 3.—Section of hard fibrous tumor, one of many taken from skin of horse. Bundles of fibres run in various directions; blood vessels very few. a, bundles of fibres showing distinct nuclei (x74); b, nuclei under higher power (x534).



FIG'S. 4 AND 5.—Section of tumor from subcutaneous connective tissue of horse. a, dense fibrous bundles; b, dense fibrous bundles cut across; c, nucleus of connective tissue cell. Note that the nuclei or cells are less numerous in this section than in Fig's. 1 or 3, Fig. 4, x74; Fig. 5, x534.

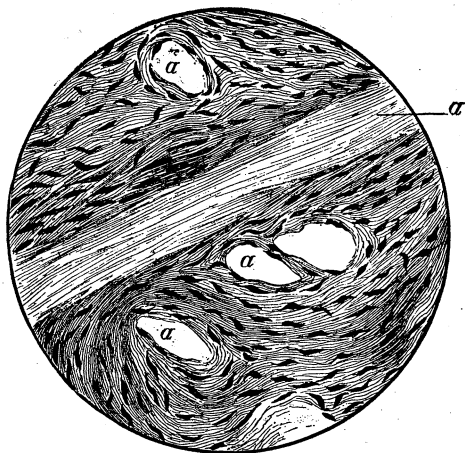
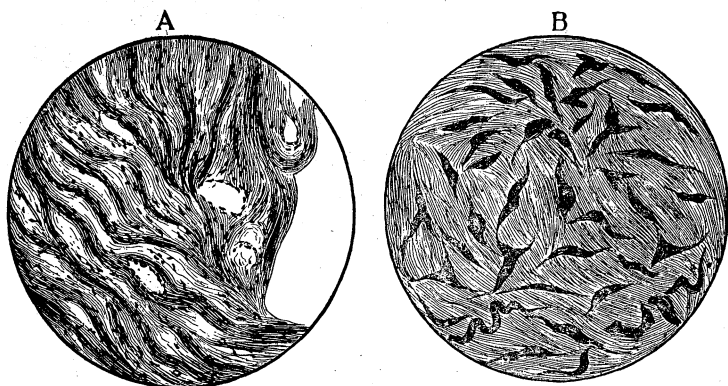


FIG. 6.—Section of fibrous tumor from subcutaneous connective tissue of horse; nuclei of cells very distinct and numerous; blood vessels large but their walls are not well organized; a, blood vessels. Magnified 534 diameters.



FIG'S. 7 AND 8.—Section of tumor from subcutaneous connective tissue of horse. A x74; B x534. Tumor smooth, firm; not very vascular; in loose capsule. Bundles of fibres wavy and nuclei of cells very distinct.

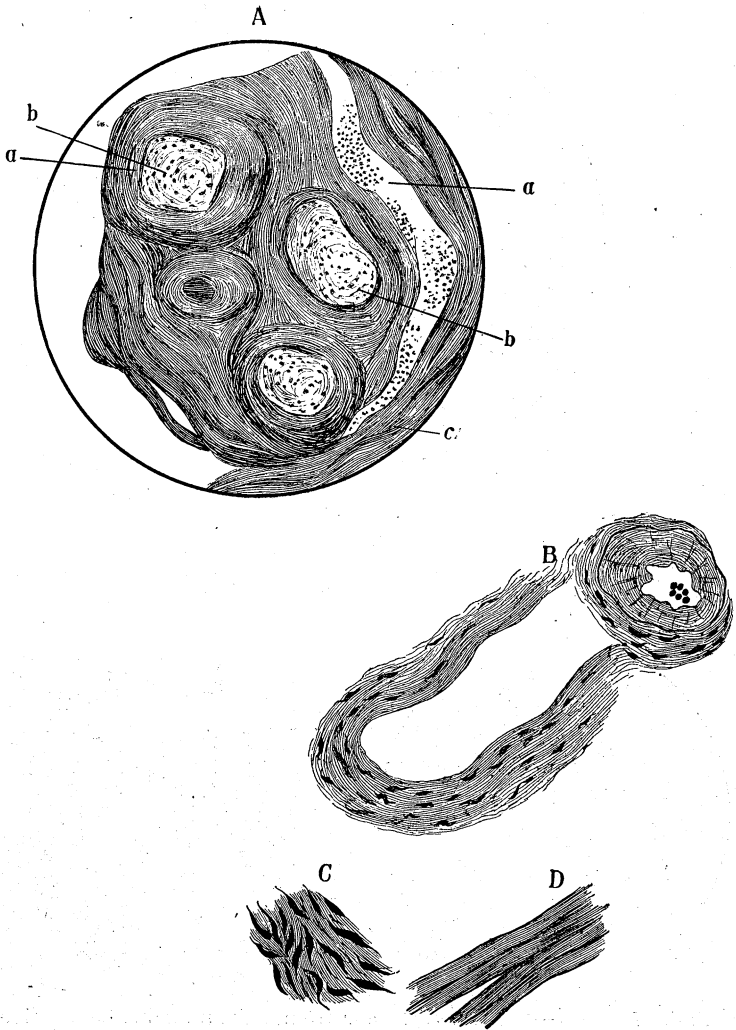


FIG. 9.—Section of multiple skin tumors, from the same horse as Fig's. 7 and 8. The blood vessels in the tumors are not well developed, but the vessels, just below the tumors in the subcutaneous connective tissue, are numerous and large. The young tumors are surrounded by concentrically arranged fibres, and young tumors are made up chiefly of young, spindle-shaped connective tissue cells.

A, (x74) a, Blood vessels; b, encapsulated multiple tumors; c, fibrous tissue. B, (x534) cross and oblique section of two arteries, just below the multiple tumors in A. C, (x534) represents b of A under a higher power. D, (x534) represents c of A under a higher power.



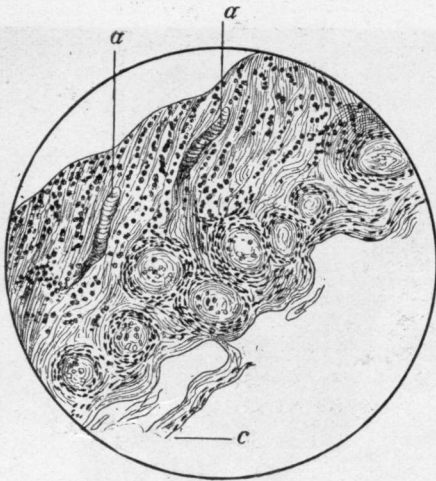


FIG. 10.- Section of multiple tumors from same horse as 7, 8, 9. a, blood vessels; b, small young fibrous tumors; c, cut off, pigmented epithelial cells (x74).

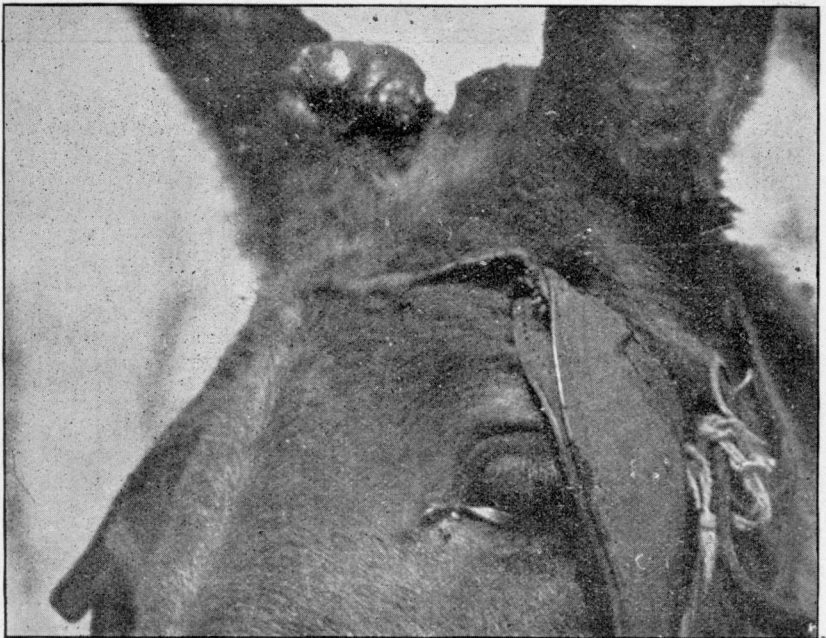

FIG. 11.

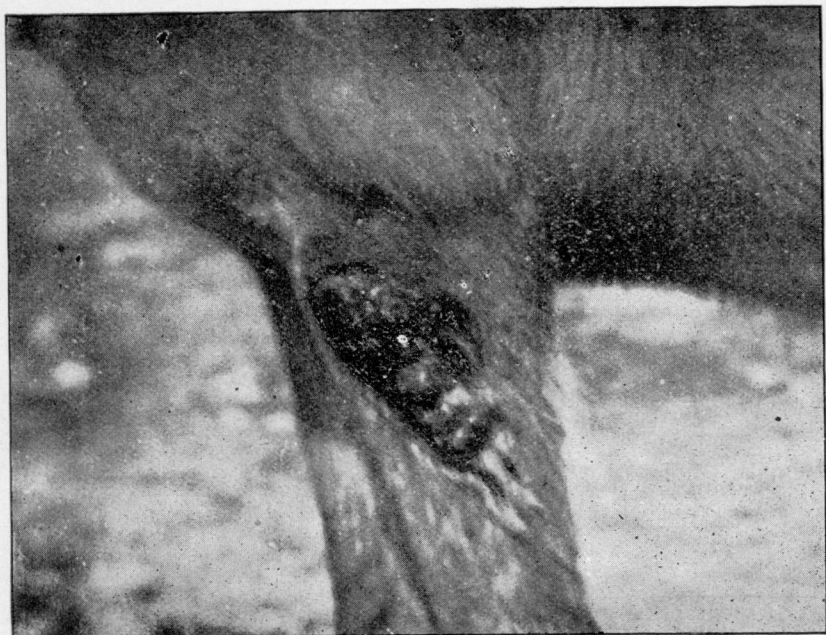

FIG. 12.

FIG'S. 11 AND 12.—Photographic representations of fibrous tumors on the ear and fore-arm; tumors have broken through the skin and look very like granulation tumors.

## APPENDIX.

*Classified List of Tumors taken from the Free Clinic Records  
for the Four Years Ending July 1st, 1896.*

---

 FIBROMAS.

1. Gray gelding, 4 years old, several tumors, excised and cauterized surfaces with thermo-cautery; results unknown.

2. Mule with a large raw tumor on lower part of right flank, one small tumor on sheath; excised, result unknown.

3. Mule with raw tumor on right ear, one on outside of left thigh, one on outside of forearm; excised; prescribed equal parts of tar and vaseline to be applied daily. Did not return. (These tumors illustrated in cuts Nos. 11, 12.)

4. Gelding with 2 large and 2 small tumors; removed with the knife and ecraseur; applied chromic acid; prescribed (c) page 318.

5. Colt, 2 years old, 1 tumor on leg, 1 on the abdomen and 1 on the ear; removed with shears and ecraseur; applied strong carbolic acid; never returned.

6. Mule with tumor on lip and one on rib region; excised and applied strong carbolic acid; result unknown.

7. Mule with skin tumor on side of abdomen; excised; applied strong carbolic acid; prescribed tannic acid 1 part, glycerine 4 parts; results unknown.

8. Mule with one small fibrous tumor on breast; excised; never returned.

9. Mule with a large "bleeding" fibroid on abdomen and several small ones on the perineum. Excised; no return.

10. Dark gray mule with about 50 fibrous tumors; largest ones on abdomen and around base of left ear; many small

ones, from the size of a pea to one inch in diameter, were located over the abdomen, on sides of thorax, in the groins and axillae, and over the limbs. There were so many small ones that some were over-looked in the process of cutting them out. Applied pulverized copper sulphate; prescribed (b) page 318. In six months, many of the small ones, that had been over-looked in previous operation, were now large enough to be easily located and removed. Two years after the second operation, three or four small tumors were found on this mule.

11. Gray horse with tumor in anterior part of a left axillae; upon cutting through the skin it was easily pressed out of its capsule; prescribed (c) page 318.

12. Mule with skin tumor on left knee; excised and applied strong carbolic acid; prescribed (c).

13. Colt, 2 years old, with bleeding tumor on fore-arm; excised; applied strong carbolic acid; prescribed (c). Never returned.

14. Gelding, 11 years old, with one large raw tumor on abdomen, a few small ones on the sheath, on the breast and in the axillae; excised and applied strong carbolic acid; prescribed (c). In six months the small tumors that were not easily located at the first operation were now distinct and readily removed.

15. Mule, 7 years old, with fibrous tumor in right groin and involving right side of mammary gland. excised; prescribed (b).

16. Mule, 10 years old, with fibrous tumor at base of ear; excised; applied strong carbolic acid; prescribed (c).

17. Mule, 3 years old, with a fibroid on right elbow for three weeks; excised; applied strong carbolic acid; prescribed carbolized oil.

18. Mule, 8 years old, with fibroid on sheath for two years; excised; applied strong carbolic acid; prescribed (c). Never returned.

19. Bay stallion, 3 years old, with fibroid on right upper eye-lid; excised; applied strong carbolic acid; prescribed carbolized oil.

20. Bay mare mule, 4 years old, with fibromas in left axillae; excised; applied strong carbolic acid; prescribed (b).

21. Mare, 3 years old, with fibroma on right ear; excised; cauterized with strong carbolic acid; prescribed carbolized oil.

22. Mule, 7 years old, with several fibromas; excised; applied copper sulphate; prescribed (b).

23. Bay mule, 5 years old, fibroid on abdomen; excised. Owing to neglect, a granulation tumor developed in a short time; it was excised; pulverized copper applied, and (b) prescribed. Never returned.

24. Sorrel gelding, 3 years old, with fibromas in right axilla; excised; applied strong carbolic acid; prescribed (b).

25. Bay mare mule, 10 years old, with large fibroid on abdomen just in front of mammary glands; excised; applied copper sulphate; prescribed (a). Never returned.

26. Black gelding, 5 years old, with a hard fibroid lying deep in the fascia of the external tibial region; excised; prescribed a 2 per cent. creolin solution. Never returned.

This tumor contained small pockets of fine chalky material and the fibrous tissue was thoroughly impregnated with lime in the central portion of the tumor.

27. Mule, 3 years old, with numerous fibroid tumors on upper eye-lid and on the breast. These tumors were so little and numerous that it was impossible to remove them all without cutting away large patches of skin. As many as practicable were cut out; applied copper sulphate and prescribed (b).

In twelve months, the little tumors that were not removed had developed until they were larger than those that were first removed; also, tumors were then visible on other parts of the body.

28. Gray mare, 4 years old, with fibromas on various parts of body. Excised; applied pulverized copper sulphate; prescribed (b).

29. Black mare, 7 years old, with fibromas on mammary gland, abdomen, groin and flank; excised; applied copper sulphate; prescribed (b).

30. Black mare, 5 years old, with small hard fibroid on border of lower jaw; cut out; applied copper sulphate; prescribed (b).

31. Bay mule, with fibrous tumors on pole and on left hind limb; excised; applied copper sulphate; prescribed (b).

32. Bay gelding, 5 years old, with fibrous tumors on the ears; cut off; treated same as No. 31.

33. Bay mule, 15 years old, with hard fibroid on left rib region, 3 to 4 inches in diameter, growing for 5 years; excised; prescribed (a). Never returned. Microscopic examination proved it to be a hard fibroid with calcareous degeneration.

34. Sorrel gelding, 5 years old, with fibrous tumor on left fore-arm; excised; applied copper sulphate; prescribed (b). Never returned.

35. Sorrel mare mule, 6 years old, with fibrous tumors on external surface of right ear; cut off; treated same as No. 34.

36. Mule, 10 years old, with fibrous tumor on right rib region, very large and hard. Excised; applied copper sulphate; prescribed (a). Never returned. This tumor had been growing for 5 years. It was a hard fibroid with calcareous degeneration.

37. Bay mule, 8 years old, with fibroid in right axilla; excised; applied pulverized copper sulphate; prescribed (a). Never returned.

38. Mule with hard fibroid in thigh region; excised; never returned. It had undergone calcareous degeneration.

39. Sorrel mule with fibrous tumor on external tibial region; excised; applied copper sulphate; prescribed 2 per cent. creolin solution.

40. Sorrel mule, 8 years old, with fibrous tumors all over the body, chiefly in the groins and axilla and on the ears. Excised (40 or 50) as many as could be easily found; prescribed (a).

41. Sorrel mule, 4 years old, with fibrous tumor on posterior surface of right knee; excised; applied copper sulphate; prescribed (a).

## GRANULATION TUMORS.

1. Mule with granulating "sores" on rib region and on breast. In curetting away the exuberant growths a slight grittiness was perceptible, indicating calcareous degeneration; this made the growths more consistent and more definitely granular. Another peculiar characteristic was observed; this hard granular growth extended quite a distance under the skin, and could be easily removed by pushing the curette up under the skin. After removing as much of the granular growths as possible with the curette, strong carbolic acid was applied and the following was prescribed: Carbolic acid, 2 drachms; Iodoform, 1 drachm; Tannic acid, 1 ounce; Glycerine, 1½ pints. Mix. Apply daily after washing. In 4 or 5 weeks the wounds had all healed and there were no more signs of their return that year. But the next spring "the same kind of sores broke out all over the body and got so bad that I took the mule off and killed him" (owner).

2. Bay mule, 6 years old, with exuberant granulations on inside of left hind pastern. Cut it off even with the surface, applied pulverized copper sulphate and then a bandage. As soon as the bandage was removed the mule was worked; the opposite foot struck the raw surface and the mule habitually gnawed it. Consequently, new growths were removed from this place eight times during the next two years. At present (June, 1896) a new growth as large, or larger than, any that were removed from the same place is now to be found; also, another tumor of the same nature has appeared, and has been removed 3 or 4 times, on the inner surface of the upper end of the canon region of the same leg. Microscopical sections of these tumors show that they are made up largely of embryonal cells not unlike the spindle cells of a sarcoma.

In one sense this tumor might be called a malignant, spindle-celled sarcoma. However, it is best to regard it as resulting and recurring from mechanical irritation, and most probably extending from the same cause. It is well to add that the mule was kept quiet only a short time dur-

ing these attempts at treatment and much of the time he was at work in the plow or wagon.

3. Mule, 12 years old, with a very large granulation tumor on inside of left hock. Caused by sticking a knife into a varicosed vein (blood spavin) and injurious applications. Sliced away the greater part of the granulations; applied pulverized copper sulphate and bandaged for two weeks; prescribed (a). Good recovery in 6 or 8 weeks.

4. Spanish Jack, 4 years old, with large granulation tumors on each limb. On one hind limb the growth covered the entire outside and part of the front surface of the fetlock, the canon and the hock. The jack was greatly emaciated and had a very poor appetite. Applied pulverized copper sulphate and bandaged as directed on page 319. This jack was kept in the college hospital and the bandages were maintained in a fixed position by keeping the animal quiet and by close attention. In nine or ten weeks the bandages were left off and thereafter only creolin washes and carbolized oil and tannic acid were applied. In about six months these places had healed and the jack was in a greatly improved condition. But from some unknown cause he was impotent; "he had no ambition." It is very probable that he was impotent when received for treatment.

Recently, Dr. W. A. Heck of Keokuk, Iowa, has been very successful in treating granulation tumors by cutting them down even with the surface and then giving internally a teaspoonful of fluid extract of ergot three times daily. The ergot tends to cut off the extra blood supply to the granulation tumor.—(C. A. C.)

#### PAPILLOMAS (WARTS).

1. Gray colt, 2 years old, with extensive growth of "seed warts" (papillomas) on inside surface of both ears. Clipped them off with the soissors; curetted the surfaces, and applied corrosives sublimate by rubbing large crystals over the raw surfaces. One week later, applied strong carbohic acid, and prescribed (c). These growths were so heavy that the ears were bent over. They never returned.



2. Colt, 1 year old, with warts on the internal surface of each ear; excised and cauterized with strong carbolic acid; never returned.

3. Filly, 3 years old, with papillomas on internal surface of each ear; curetted away the warts; applied strong carbolic acid; prescribed (c). Some of the warts were not entirely removed; hence, a second operation was required.

4. Bull calf, 2 years old, with papillomas on right thigh and groin; excised; applied strong carbolic acid; prescribed (c). Never returned.

5. Dog with papilloma on toe of front foot; excised; cauterized with strong carbolic acid; never returned.

6. Bay filly, 18 months old, with papillomas on internal surface of each ear; excised; applied pulverized copper sulphate; prescribed (c).

7. Hen, 2 years old, with two abnormal growths on one wing. Microscopic examination proved them to be composed of imperfectly developed papillae and feathers.

8. Grade Jersey heifer, 2 years old, with numerous papillomas on abdomen and limbs; excised all that were large enough to find; applied pulverized copper sulphate. In the course of a year, many of those that were invisible at the time of the operation developed into prominence.

9. Sorrel mare, 5 years old, with papillomas on inside surface of each ear; cut and curetted them away; applied copper sulphate; prescribed (c). Never returned.

10. Bay stallion, rising 3 years old, with papilloma on end of the tail; clipped it and part of tail off with bone cutting forceps; prescribed (a). Never returned.

#### SARCOMAS.

1. Gray mare with melanotic (pigmented) sarcoma just below the inferior commissure of the vulva; removed with the ecraseur; cauterized with strong carbolic acid; never returned.

2. Bay mare mule, 6 years old, with sarcoma in eye socket; removed the entire contents of the eye socket; the tumor returned, invaded the frontal sinus and possibly the

cranial cavity; mule died in about five weeks after the operation.

3. Gray mule, 24 years old, with melanotic sarcoma on left buttock; excised; prescribed "white lotion." Result unknown.

4. Pointer dog, 8 years old, with melanotic sarcoma on side of scrotum; excised and wound healed nicely in short time. Six months later a great number of tumors appeared in the subcutaneous connective tissue in various parts of the body; the dog exhibited symptoms of indigestion, lung trouble, and brain lesions (inability to properly control voluntary movements). Post mortem revealed numerous melanotic sarcomas in the pleura and peritoneum and two in or under the pia mater. Microscopic examination showed them to be round-celled sarcomas with less pigment than is usually found in melanotic sarcomas of the horse.

5. Gray mare, 17 years old, with numerous melanotic sarcomas in the subcutaneous connective tissue, scattered over the surface of the body. There were some signs that the lungs and other internal organs had been invaded. Only one large tumor was removed.

#### CARCINOMAS.

1. Mule with fungus-like growth on membrana nictitans (eye washer); removed with the shears the tumor and the "washer." The tumor returned in about six months; removed it again; result unknown.

2. Black Essex sow, 3 years old, with tumor in mammary gland; removed by excision three times within a year; at present no sign of return or of extension. Microscopic examination proved it to be a round-celled carcinoma.

3. Sorrel horse with a malignant tumor involving the right side of the face and extending from the right eye downward and forward into the right maxillary sinuses and destroying all the outer wall of the sinuses with which it came in contact. The animal was destroyed.

Reports of all infectious, contagious or peculiar diseases occurring in Alabama will be thankfully received by the Veterinary Department.